



## COX® TECHNIC FLEXION-DISTRACTION CASE REPORT OF 35 YEAR OLD MALE C6-C7 CERVICAL POSTEROCENTRAL DISC PROTRUSION

Dr. Joel Dixon (B. APP Sci (Chiro) J.P, Certified Cox Practitioner)  
From Melbourne Spine Clinic in Melbourne, Victoria, Australia.

### Abstract

**Objective:** The purpose of this paper is to discuss a non-surgical method of treatment for a cervical disc protrusion with Cox® Technic flexion distraction method.

**Background:** A 35-year-old man complained of severe neck pain and spasms, pain radiating down his left arm and upper back. Cervical spine plain film radiographs showed mild C6/C7 osseous degenerative changes. Cervical magnetic resonance imaging revealed a moderate-sized left posterolateral disc protrusion at C6/C7 causing severe foraminal stenosis.

**Methods:** The patient was diagnosed with cervical radiculopathy with a disc syndrome at C6/C7 and received treatment in the form of Cox flexion distraction manipulation and adjunctive therapies. VAS was used to objectify the pain.

**Discussion:** Cox flexion distraction is a method mainly associated with treatment of the lumbar spine. It may be an effective therapy for the treatment of cervical disc syndromes as well, although further studies are required.

**Conclusion:** In this study, a complete resolution of the patient's subjective complaints was achieved.

### Introduction

There have been numerous studies that have documented the benefits of Cox flexion distraction methods on the lumbar spine<sup>1-4</sup>. Cox flexion distraction is a research documented spinal manipulative technique that is widely taught to relieve back pain, neck pain, arm pain, spinal stenosis, post-surgical continued pain and pregnancy related back pain<sup>4</sup>. Cox flexion distraction provides a widening of disc space as well as a decrease in intradiscal pressure. The basis of Cox flexion distraction manipulation is to open the posterior motor unit to allow a greater sagittal diameter within the vertebral canal<sup>3</sup>.

In most cases, where there is neck pain, there exists arm pain as well<sup>4</sup>. Neck pain on its own may be due to the pressure on the spinal nerve, and is not as severe, whereas in conjunction with arm pain, indicates that there may be more pressure<sup>3</sup>. Size of the canal may play a role in the amount of pain where a smaller canal space with a disc herniation will produce greater pain<sup>1,6</sup>. With the Cox Technic method, the optimal goal is to reach a state of relief of no pain and with an overall improvement on the disc dysfunction without any surgery, as shown in the case studies.

## Case Study

In this case, we have an ectomorphic 35 year old, white, married male who was first seen on January 27, 2012, for the chief complaint of a chronic pinched nerve in the lower cervical region with radicular pain into the left neck, shoulder and down to the posterior lateral margin of the left arm. The pain was described as a dull ache, with constant intensity and rated 2.3 on a VAS of 0-10. The pain had been interfering with his sleep and work. Movement of the neck and compression to the neck region increased the aggravation. The onset of the pain was reported to have been 8 months ago with no similar symptoms prior to the onset. There was an acute exacerbation episode 48 hours prior to first visit. The patient's case history included a previous car accident, approximately 12 years ago where, as a pedestrian, he was hit by a car and knocked unconscious. The patient has never used any crutch or cane for support. His previous treatments included chiropractic, massage, medications such as NSAIDS and HBOT. He has had a history of bone fracture (unknown location), and was hospitalized for surgery. His spinal examination, blood test, spinal X-ray and urine test were obtained in the last 6 months. His lifestyle habits included no alcohol, coffee, tobacco or drugs. He exercises quite often and his appetite and sleep were normal. He takes daily supplements such as magnesium and fish oil.

## Examination Findings

Upon examination on January 27, 2012, there was found to be a decrease in cervical spine, both passive and active ROM. Flexion was 50°, full and pain free. Extension was reduced to 30°. Both his left and right rotation was 70° and caused a pulling sensation on his neck. His lateral bending left and right was 35° with no symptoms of numbness. Orthopaedic examinations included positive indications on left cervical compression and positive sign on left cervical foraminal compression. Pin wheel dermatomal testing revealed a decrease in sensory response at C6-C7 on the left arm. The patient's reflexes were normal in both arms for biceps, triceps and radial reflexes at +2. A positive Bakody's sign was noted, in as much as placing his hand on his head relieved the symptoms. Upper extremity muscle testing revealed the patient's muscles to be strong at +5/5. However, there was spasm produced with resisted wrist flexion.

## Imaging

Three MRIs have been performed over a period of 8/12. On July 26, 2011, a standard MRI image was taken at the Melbourne Radiology Clinic. The history included previous car accident 12 years ago and C5/C6 and C6/C7 pathology. The findings included correlation to the MRI examination from the cervical spine taken in June 2011. There was a loss of cervical lordosis found in mid cervical and mid lumbar region. Minimal retrolisthesis of C5 on C6 and L5 on S1. Minimal foci degeneration observed at the C5/C6, T7/T8 to T9/T10, L2/L3 and L5/S1. In conclusion, there was a central to left paracentral foraminal protrusion at C6-C7 disc resulting in mild central canal and severe left neural exit foraminal stenosis and a mass effect upon the exiting left C7 nerve. This is not significantly altered when compared with the previous examination. No neural compressive

pathology of the thoracolumbar spine. Mild retrolisthesis of L5 on S1 with mild bilateral facet arthropathy at this level. Third imaging taken prior to start of the treatment on September 9 2011, concluded that there was a minimal decrease in the size of the disc osteophyte complex at C6/C7, now contacting the cord and resulting in additional mild central canal stenosis.

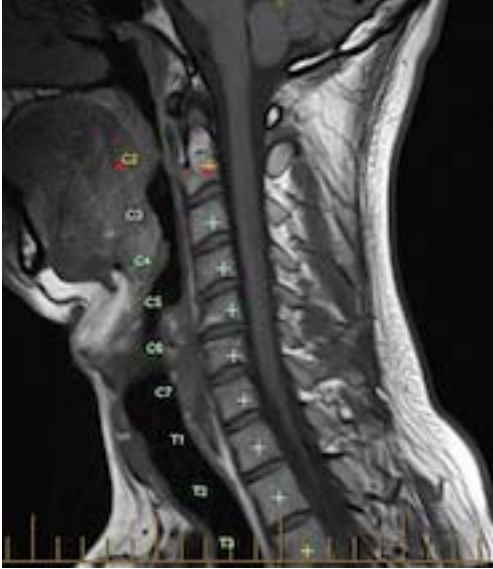


Figure 1(T1: 26/07/2011)

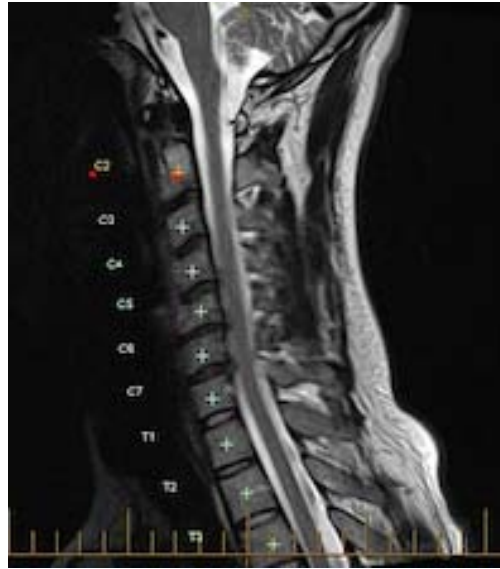

Figure 2 (T2: 26/07/2011)

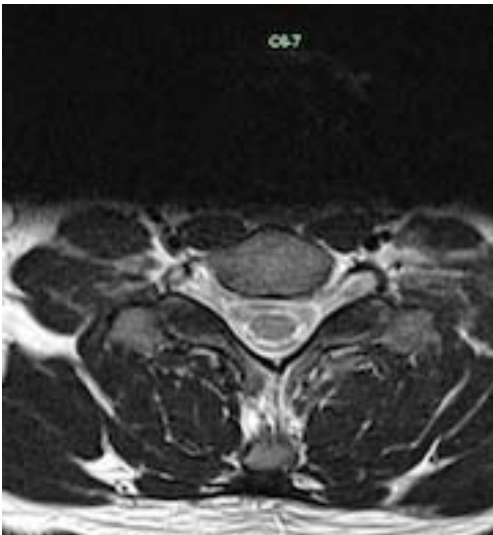


Figure 3 (T1 Axial: 26/07/2011)

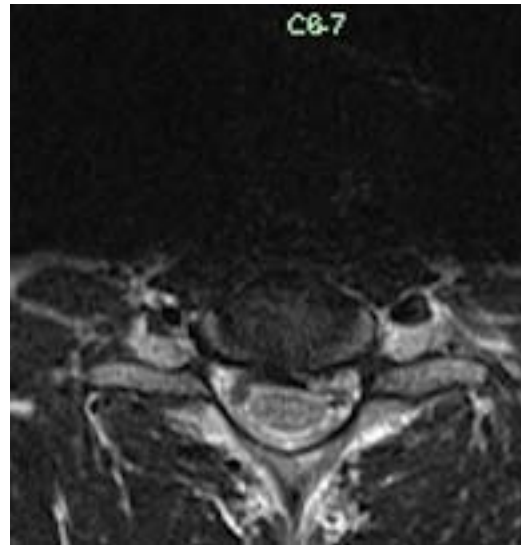


Figure 4 (T1 Axial: 26/07/2011)

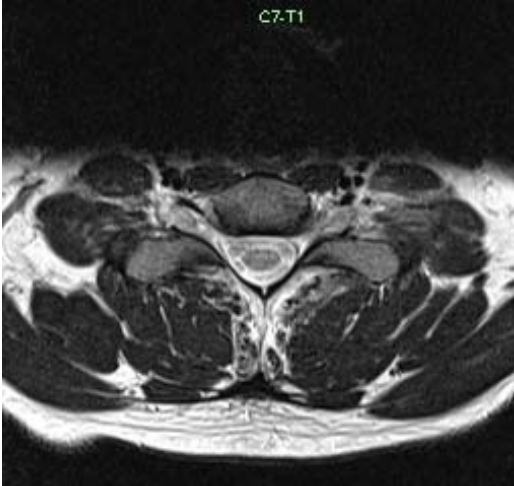


Figure 5 (T2 Axial 26/07/2011)

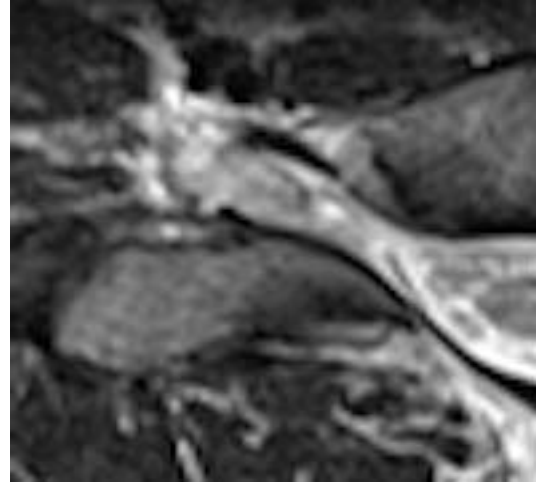


Figure 6 (Dorsal Root Ganglia C7-T1)

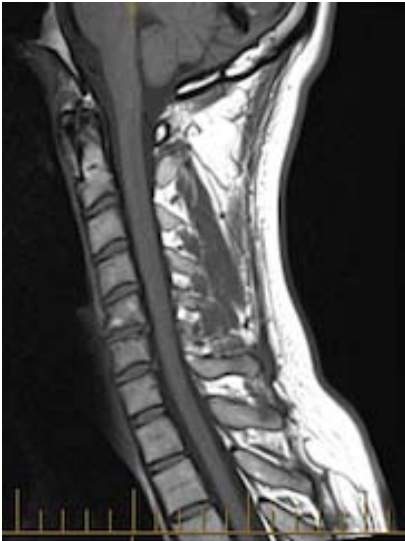

Figure 7(T1: 09/09/2011)

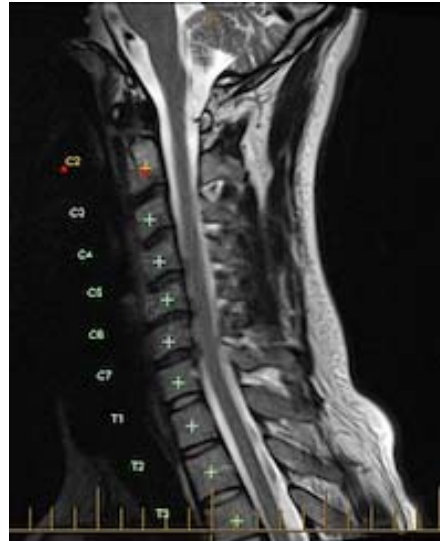

Figure 8 (T2: 09/09/2011)

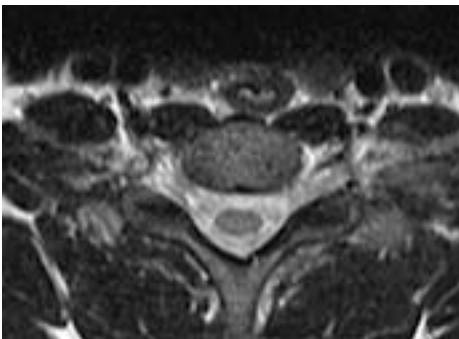


Figure 9(T2 Axial: 09/09/11)

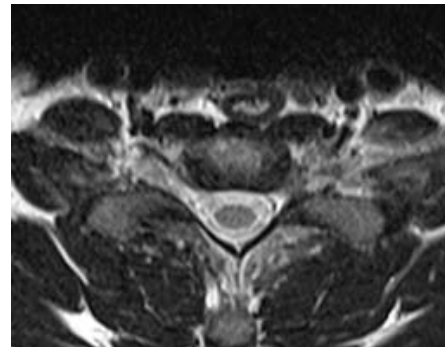


Figure 10 (T2 Axial: 09/09/2011)



## Diagnosis

The patient was diagnosed with a chronic C6-C7 disc protrusion syndrome with radiculopathy down the left arm. This is consistent with severe left foraminal stenosis resulting in compression of the exiting C7 nerve root.

## Treatment and Management

Treatment procedures consisted of physical therapeutics and application of Cox flexion distraction technique with a cervical apparatus on a standard Cox flexion distraction table. Because of the subjective and objective findings, the Cox flexion distraction technique was used with the cervical headpiece at 0° lateral flexion before the flexion procedure. Later therapy included cervical Cox flexion distraction with lateral flexion.

The treatment sessions for this patient were a combination of four by four sets of Cox flexion distraction performed, each consisting, of one second holds. Protocol 1 was administered to the patient with the head support on. The chiropractor's contact was at the C5-C6 level. Treatments were performed three times a week for two weeks, after which the frequency was decreased progressively, as indicated by the patient's progress, but maintained at a minimum of once a week. The patient noted immediate relief after the second treatment, stating that he had significantly less numbness and fewer spasms. However, after the first treatment, the patient reported experiencing a headache and difficulty sleeping, which had progressed for the next few nights. Ergonomic changes were recommended at his work setting in conjunction with the start of treatment. Diet and exercise were maintained as before with additional daily intake of chondroitin sulphate supplement (500 mg/day). Treatment was continued and isometric strengthening exercises were introduced resulting in only minimal, intermittent symptoms being reported. These subjective complaints consisted of occasional mild spasms in the forearm as well as occasional transient numbness, both of which were position dependent. The patient noted some transient return of his radicular symptoms whenever treatments were withheld. He was therefore treated approximately once a week, which seemed to control his symptoms. Over a three month period he was treated approximately 38 times and was virtually asymptomatic at the time of his release from care.

On March 19, 2012, standard MRI imaging was performed at Victoria House Medical Imaging, where a direct comparison was made to the previous MRIs from July and September 2011. The MRI is post FD Cox treatment at Melbourne Spine Clinic, Malvern.

The findings were:

C2/C3, C3/C4, C4/C5: Normal

C5/C6: Mild disc bulging causes mild thecal sac indentation. No canal or foraminal stenosis found. No nerve impingement found. Disc is mildly desiccated with mild Modic type 2 fatty end plate degenerative change.

C6/C7: the previously demonstrated left posterolateral disc protrusion has resolved in the interval period. There is no significant cord compression or nerve impingement. Minor residual broad based disc bulging.

C7-T1 is normal. The cervical and upper thoracic spinal cord to T3/4 is normal. Normal craniocervical junction. Cervical facet joints are relatively preserved.

In conclusion: the previously demonstrated left C6/C7 disc protrusion has resolved. Minor C4/C5, C5/6 and C6/7 disc bulging.

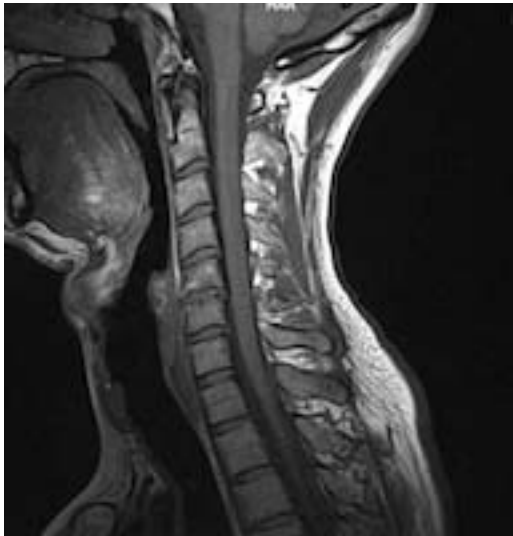


Figure 11 (T1: 17/03/2012)

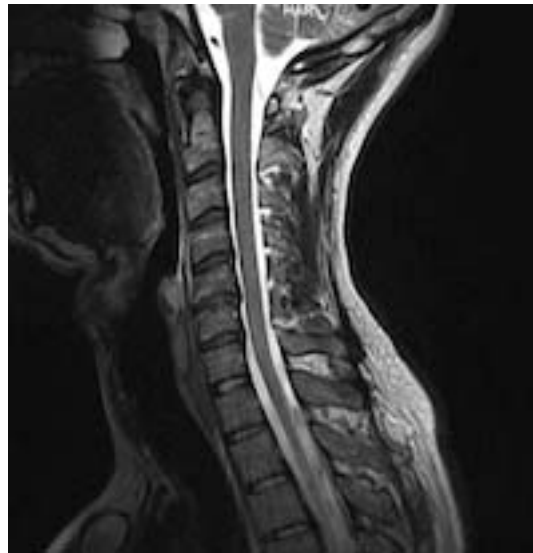

Figure 12 (T2: 17/03/2012)

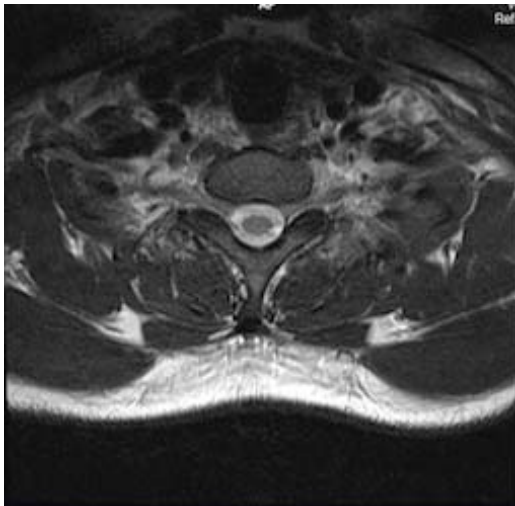


Figure 13 (T2 axial C6-C7: 17/03/2012)

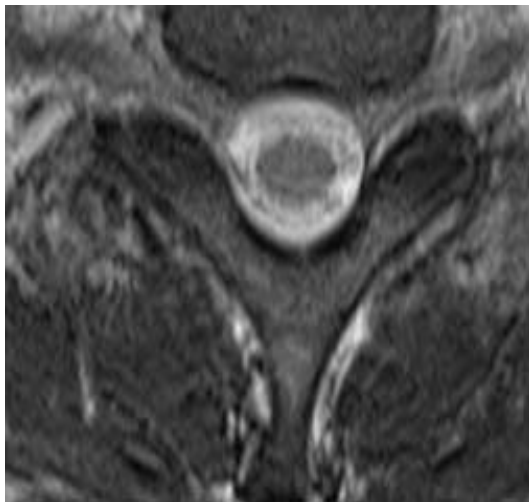


Figure 14 (T2 axial C6-C7, 17/03/2012)

At the 6 month follow up, the patient reported being symptom free and his objective and neurologic status was unremarkable.

## Discussion

Prior to his first Cox flexion distraction treatment the patient was asked to use a VAS scale to describe his pain on a scale of 1-10 with the result being 2.3. Following the first treatment, he described his pain level had increase to 2.7, and had experienced a post treatment headache. Throughout the treatment process his pain level measurements decreased to 0.3, with no headache reported, his sleeping patterns which had been described as “poor” improved to “no difficulty sleeping”, with a decrease of pain in his arm and neck.

The effects of traction on the spine have been documented. A study by Onel et al<sup>3</sup> involving the use of computed tomography reveals that traction widens the disc space, causing decreased intradiscal pressure. Liang et al<sup>2</sup> found that flexion increased dural sac capacity up to 6 mm in comparison with extension; the authors suggest that flexion might diminish symptoms that are affected by a decrease in spinal canal capacity. Epstein et al<sup>5,6</sup> used MRI to document that cervical flexion reduces disc herniation whereas extension increases disc herniation.

## Conclusion

Cox flexion distraction technique uses both the advantages of flexion forces and distraction forces<sup>6</sup>. Nerve root irritation can benefit from the mechanisms of flexion and distraction<sup>5</sup>. There is research that supports the effectiveness of Cox flexion distraction on the lumbar spine<sup>6</sup> and the success of this case demonstrates that Cox flexion distraction might be an asset in the management of cervical spine nerve root irritation. It is our opinion that randomized trials need to be performed to determine the validity of Cox flexion distraction for treating the cervical spine.

## References

1. Cox J, Shreiner S. Chiropractic manipulation in low back pain and sciatica: statistical data on the diagnosis, treatment and response of 57 consecutive cases. *J Manipulative Physiol Ther* 1984;7:1-11.
2. Cox J. *Low back pain: mechanism, diagnosis, and treatment*. 5th ed. Baltimore (MD): Williams & Wilkins; 1990. p. 89,123,451,475.
3. Kruse R et al. Treatment of cervical radiculopathy with Cox flexion distraction. *JMPT* ; 2001 Vol 24, issue 3, p.206-209.
4. Gudavalli S, Kruse R. Foraminal Stenosis with radiculopathy from a cervical disc herniation in a 33 year old man treated with Cox flexion distraction manipulation. *JMPT* 2008, June 31(5):376-80
5. <http://www.coxtechnic.com>
6. Cox J. *Low Back Pain: Mechanism, Diagnosis, Treatment*. 7th edition-2011