



L5-S1 Extruded Disc Relieved with Cox® Technic Decompression Spinal Adjusting

submitted by
Joseph d'Angiolillo DC
11 Clyde Road, Suite 103
Somerset, NJ 08873
(732) 873-2222

This is a case study of a patient with an extruded disc at L5-S1 who responded beautifully to the Cox® Decompression Spinal Adjustment.

History:

The patient is a 34 year old well nourished male of Indian descent presented himself on June 28, 2010 for examination and treatment of left sided lower back pain radiating into the left lower extremity. He related that approximately one and a half weeks prior to entering my office he was warming up to play cricket, did a twist and felt the rapid onset of left sided lower back pain. He described the quality of his pain "like a sharp dagger was being stabbed into his lower back." The next day the pain reduced by about 90% after he treated himself with "hot water baths." For the next three days the pain eased up and he felt "normal," then about a week prior to entering my office the pain went down into the side of his left thigh and lower leg. The side of his left foot hurts badly and has a tingling sensation. The calf of his left leg cramps and spasms when walking. Initially coughing and sneezing aggravated his left lower back but does not aggravate his pain now.

Four days ago he consulted his primary care physician who prescribed naprosyn.

Examination:

June 28, 2010: revealed the patient was able to ambulate with a normal gait, unassisted, and was able to move about the examination table with out much distress. His posture was altered with a lower right iliac crest, lower right shoulder and a lower right occiput. The dorsolumbar ranges of motion were pain free and unrestricted except for anterior bending produced left calf pain at 70 degrees. Heel walk and toe walk were essentially negative. Bechterew's Sign was essentially negative on the right; on the left produced pain into the left calf. The Leg Drop Test was essentially negative. The Fabere Patrick's Test, Nachlas Test, Femoral Stretch Test, Yeoman's Test were all essentially negative bilaterally. The straight Leg Raiser was bilaterally restricted at 60 degrees due to tightness in the hamstrings. The Fluid Motion Test revealed a

fixation of the left sacro-iliac joint. The Patellar reflexes were +2 bilaterally. The Left Achilles was +1 and the right Achilles was +2. The dermatomes of the lower extremity were within normal limits bilaterally using a Whartenberg Pinwheel. Paravertebral muscle spasms ranged from the lower thoracic spine to the iliac crests. Tenderness on digital pressure was present from L2 to S1 and at the left sacro-iliac joint.

Radiographic Examination:

Two lumbopelvic films were taken. Analysis of these films reveals the following: essentially negative for evidence of recent fracture as visualized. Facet tropism is noted at the L4-L5 joint level. The L5-S1 disc space is thinned. The lateral film reveals anterior weight bearing of the lumbar spine. The A-P film reveals a lower left sacral base along with a left lateral lumbar curvature with the apex located at L3.

Initial Impression:

Left sided S1 radiculopathy and paresthesia.

Treatment:

Cox Decompression Spinal Adjustments, long Y axis traction, along with trigger point ultrasound, electrical muscle stimulation, ice packs/hot packs as needed. Initial course of care three times per week for four weeks or until pain reduction of 50% is achieved, with a re-evaluation at the conclusion of this trial of care to determine the patient's future needs.

Treatment Goals:

To reduce the patient pain level by 50% within one month of care. If the patient does not improve during this trial of care, I may consider referring the patient for an MRI of the lumbar spine or for a consultation with a neurosurgeon.

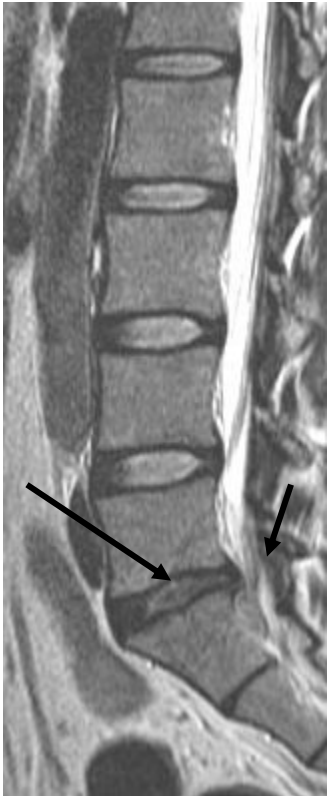Discussion:

The patient presented himself on June 28, 2010, and received three treatments through June 30, 2010, to the lumbar spine using the Cox Technic treatment protocols on The Cox 7 adjusting table, along with trigger point ultrasound. I was leaving for vacation for nine days beginning on July 1, 2010, the patient was beginning to feel better, and he was given the option of continuing care with another physician or waiting until I return from vacation to resume care. He chose to wait for my return.

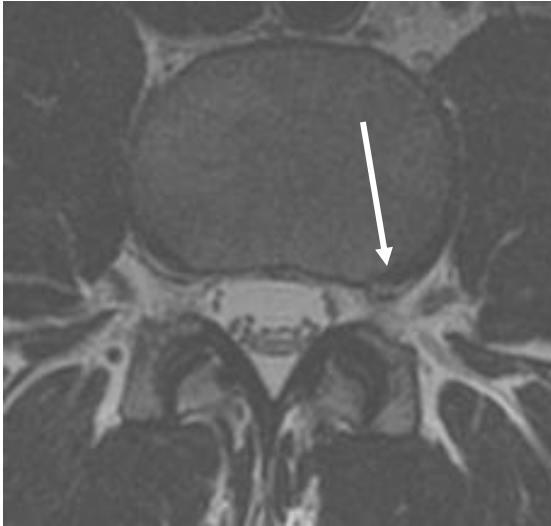
Upon my return the patient related that during the past week the tingling at the side of his left foot became more noticeable, the calf of his left leg had begun to cramp more and that he was now unable to toe walk on his left foot.

I pre-certified an MRI for the patient (The patient's insurance carrier requires pre-certification for specialized studies.) which was performed on July 16, 2010. The MRI revealed a moderate left paracentral disc extrusion at L5-S1 impinging upon the traversing left S1 nerve root.

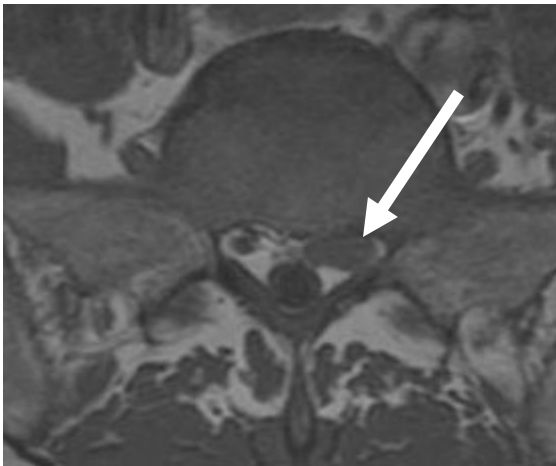
MRI Imaging:



"Mild loss of disc height and signal at L5-S1 (large arrow). The conus terminates at the mid L2 level and is normal in signal. There is mild congenital spinal canal stenosis (small arrow)."



"At L4-5, there is minimal disc bulge (See arrow.) and mild bilateral facet and ligamentum flavum hypertrophy without significant central canal or neural foraminal narrowing."



"At L5-S1 there is a mild disc bulge and a moderate left paracentral disc extrusion which extends inferiorly 1 cm into the left S1 lateral recess. (See arrow.) It impinges upon the traversing left S1 nerve root sleeve. There is a mild foraminal osteophyte/broad based disc protrusion. There is mild bilateral facet hypertrophy with mild central canal narrowing and left lateral recess stenosis. There is mild left neural foraminal narrowing."

I modified his treatment protocols to include long Y axis lumbar spine traction using The Cox 7 Table along with electrical muscle stimulation and hydrocollator therapy prior to performing the Cox Decompression Adjustment. From July 9th to July 16th the patient's pain was reducing, the tingling sensation at the side of the left foot was gone and the patient's calf strength was returning.

On July 20, 2010, the day I received the MRI report, the patient related that his left leg was feeling stronger and that he was now able to toe walk. The side of his left foot still felt numb.

At the patient's next visit, July 24, 2010, the numb sensation was isolated to a quarter size circle at the bottom of his left foot.

The patient was seen three more times from July 24th through August 2, 2010, with the patient reporting that he no longer had any pain or numbness and that he felt that his strength in his leg and foot were back to 100%.

The patient was seen 13 times between June 28, 2010, through August 2, 2010, with the outcome exceeding my initial treatment goals.

I highlight this case as there are a few points that may be used as learning moments.

The first sign that an extrusion of the disc may have occurred is that coughing and sneezing previously caused an increase in pain (the disc was contained) and then no longer caused pain (the disc was extruded). The DeJerine Triad produces an increase in pain by increasing the intraspinal pressure. If the patient's pain is the result of a disc protrusion, increasing the intraspinal pressure by coughing, sneezing or straining may exacerbate the pain. Once the disc is extruded and no longer confined by the posterior longitudinal ligament, pain is not likely to be exacerbated by increasing the intraspinal pressure.

Many patients as well as physicians want a linear upward progression of symptomatic improvement. This case reveals that "bumps in the road" may occur, with a patient worsening during the course of a treatment program. (**Editor Note:** For both the patient and treating doctor, the Cox® Technic System of protocols explains that true healing is when the pain goes away more than it comes. The patient education booklet - *Low Back and Leg Pain* - emphasizes this point.) Prior to my leaving on vacation the patient was beginning to feel better; his pain was easing up. Upon my return, his clinical picture had worsened. With the training provided by the Cox® Technic Seminars, it is less stressful handling such a challenge. Tolerance Testing and staying within the protocols lends to greater confidence in knowing when to continue with your treatment and when to refer the patient for a second opinion.

Respectfully Submitted,
Joseph C. D'Angiolillo, D.C.

Editor Note: The greatest strength of this paper is the return of motor power under conservative care including Cox® Technic. Note that on July 10, the patient had weakness of the calf muscles and couldn't walk on his left toes. From July 9 to 16, he began to have return of the calf muscle power and on July 24 had total return of strength to the left calf as he could walk on his left toe with normal motor strength. This is a valuable example of return of motor power under Cox® Technic Flexion Distraction and Decompression Spinal Manipulation.